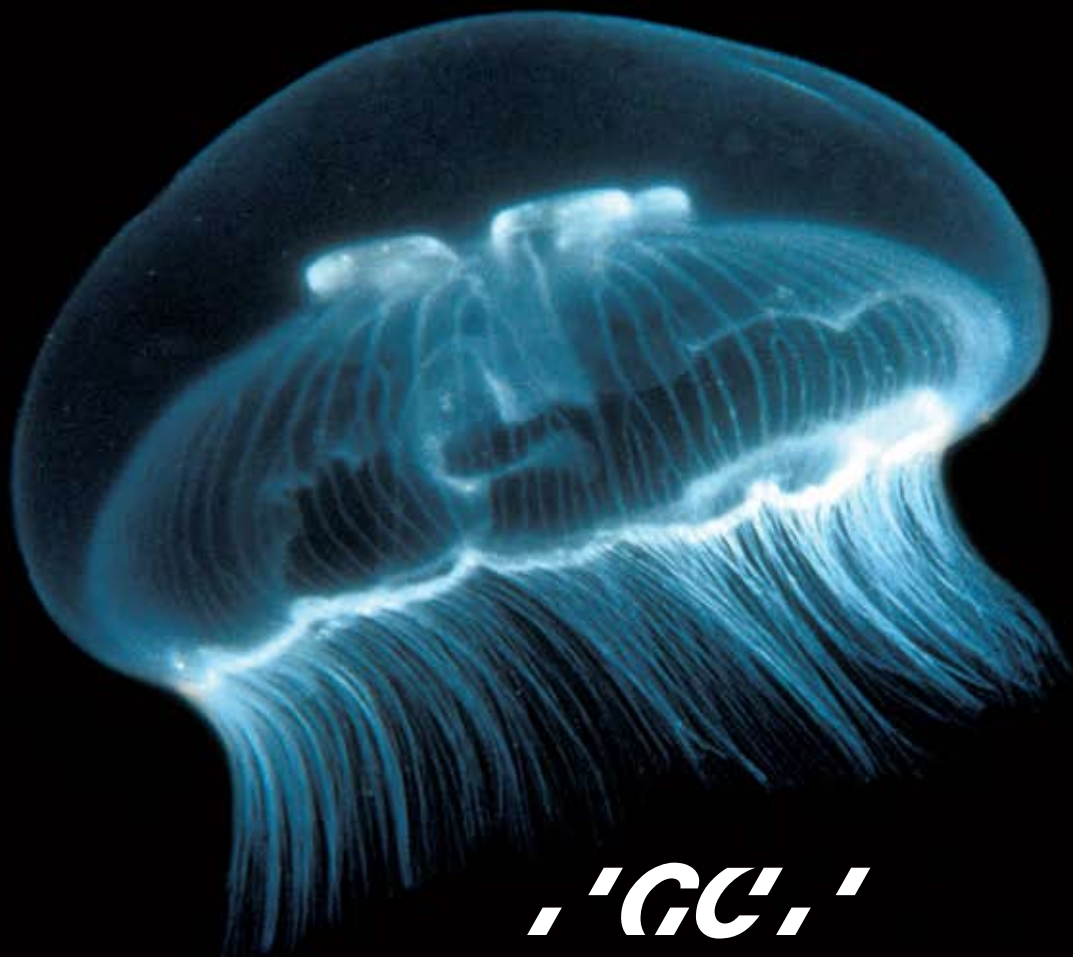


Fuji IX GP **EXTRA**

Extra TRANSLUCENCY

Extra fast Extra fluoride



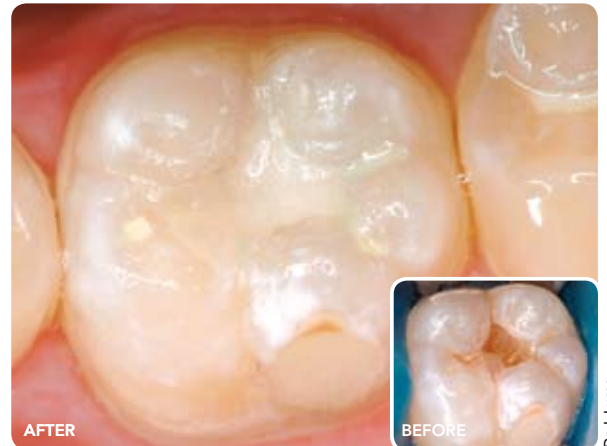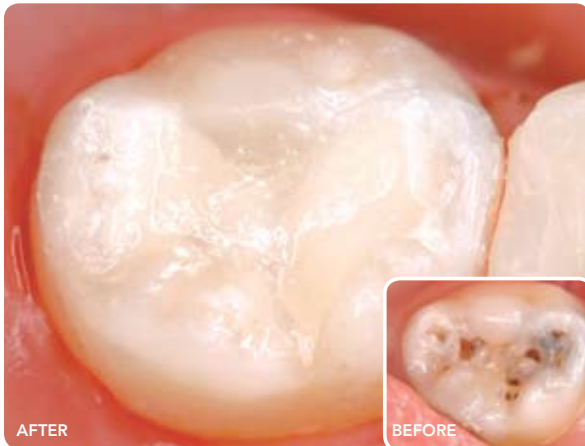GC

GC'S ONGOING COMMITMENT to glass ionomer research and innovation has led to the next significant evolution in Fuji IX GP technology.

Advances in glass technology have resulted in the development of a high-strength glass ionomer cement with greater translucency, superior shade matching ability, significantly higher fluoride release and an even faster

setting reaction. Fuji IX GP EXTRA offers the confidence of a formulation used in more than 200 million restorations and the extra level of innovation from the world's number 1 manufacturer of glass ionomer cements.

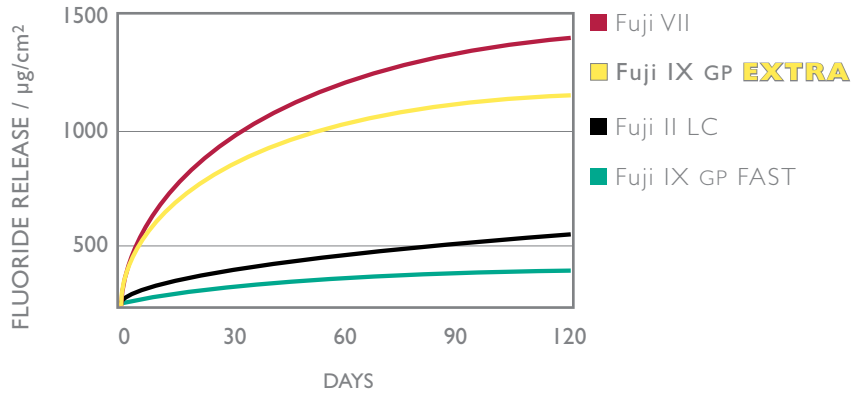
Fuji IX GP EXTRA



Fuji IX GP EXTRA

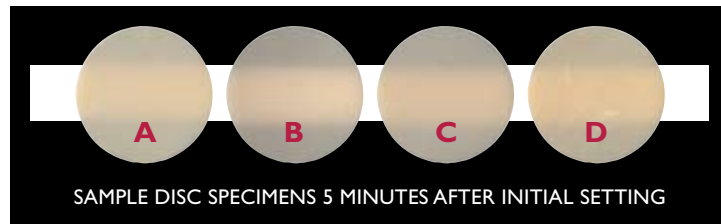Extra FLUORIDE

A new glass formulation has enabled a substantial increase in the amount of available fluoride to provide even better protection against continuing caries.



Extra TRANSLUCENCY

Research into light transmission through restorative materials identified how to achieve a better shade matching ability from high strength glass ionomer cements.

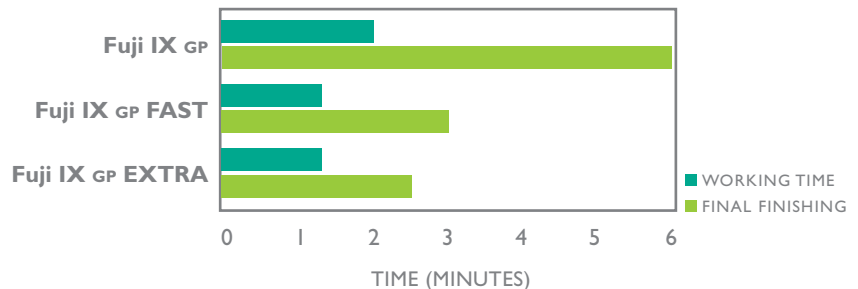


- A** – RIVA SC* A3
- B** – Fuji IX GP EXTRA A3
- C** – Fuji IX GP A3
- D** – KETAC MOLAR† A3

* RIVA IS A TRADEMARK OF SDI LTD † KETAC MOLAR IS A TRADEMARK OF 3M.ESPE

Extra FAST

Further accelerating the glass ionomer setting speed reduces the moisture critical period and placement time. You can now finish and polish Fuji IX GP EXTRA just 2½ minutes after start of mix.



GC GLASS IONOMER CEMENTS are ESSENTIAL in every dental practice

Glass ionomer cement is clinically proven as the most successful adhesive system!

In a recent systematic review of adhesive clinical trials, glass ionomer cement was ranked number 1 delivering superior retention and clinical performance over resin adhesive systems (ie superior to etch and self etch, 3-step, 2-step and 1 step adhesives)*.

* Peumans M, Kanumilli P, De Munck J, Van Landuyt K, Lambrechts P, Van Meerbeek B. *Clinical effectiveness of contemporary adhesives: A systemic review of current clinical trials.* Dent Mater 2005;21:864-881.

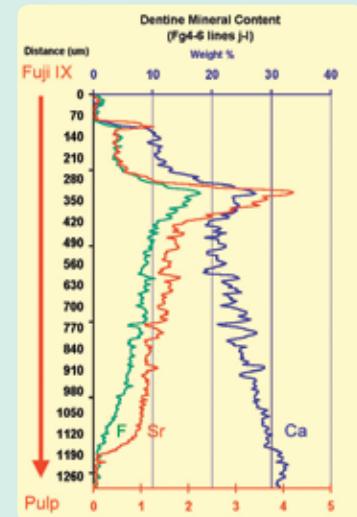
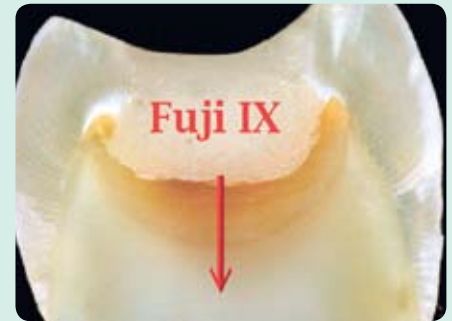Why is Fuji IX GP (EXTRA, FAST or Regular) so effective as the adhesive interface?

- Glass ionomer cements are water-based cements with a unique matrix structure ideally suited to the oral environment
- Fuji IX GP is moisture tolerant during placement**

** Fuji IX GP requires protection from moisture contamination for the period following placement till the initial set has been reached. For Fuji IX GP EXTRA this time period is 2'30".

- Fuji IX GP has a free flowing consistency to ensure optimum adaptation and adhesion
- Fuji IX GP will chemically bond to dentine, enamel and cementum
- This chemically fused seal is strong and stable
- Fuji IX GP absorbs stress to help maintain the long term integrity of the adhesive interface
- Pulpal fluid flow does not degrade the adhesive interface (as happens with resin adhesive systems)
- Fuji IX GP matures and strengthens in the oral environment
- Fuji IX GP protects surrounding tooth structure through release of fluoride and strontium ions
- Fuji IX GP has an initial antibacterial effect due to low pH
- Good biocompatibility helps achieve a positive pulpal response.
- Fuji IX GP has a similar coefficient of thermal expansion to dentine

- Fuji IX GP will help stimulate internal remineralisation releasing strontium and fluoride ions which contribute to the hardening process



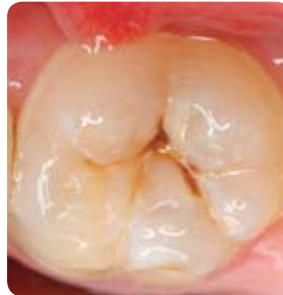Chemical exchange between glass ionomer restorations and residual carious dentine in permanent molars: An in vivo study. Journal of Dentistry, 34 (2006) 608-613. Ngo H, Mount GJ, Morris M, McIntyre J, Tuisuva J, Von Dousa R.

Fuji IX GP EXTRA puts a new PERSPECTIVE on restoring the initial carious lesion

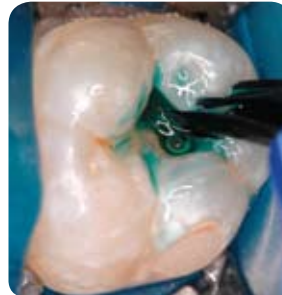Minimal occlusal restorations in permanent teeth

The combination of Fuji IX GP EXTRA and G-COAT PLUS gives a fast, minimally invasive technique for aesthetic restoration of initial occlusal lesions up to one third the inter-cuspal distance in size.

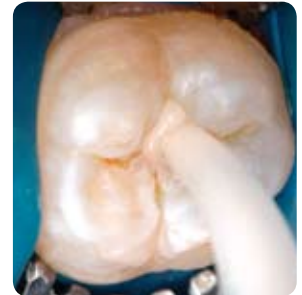The combination of Fuji IX GP EXTRA and G-COAT PLUS gives a permanent restoration with strength, wear resistance, durable adhesion and maximum protection for the tooth.



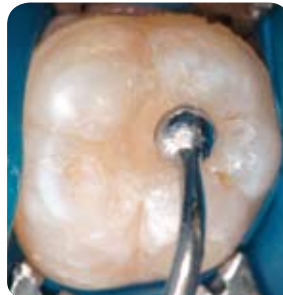Occlusal caries



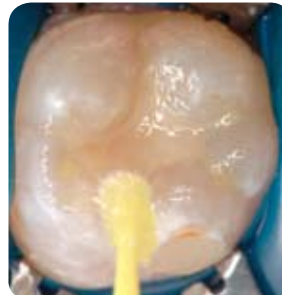Apply conditioner for 10 seconds



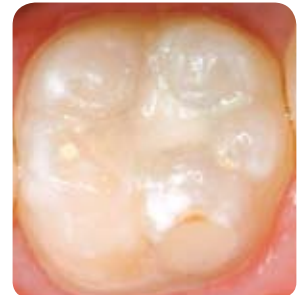Inject Fuji IX GP EXTRA



Contour occlusal anatomy



Apply G-COAT PLUS and light cure



Finished restoration

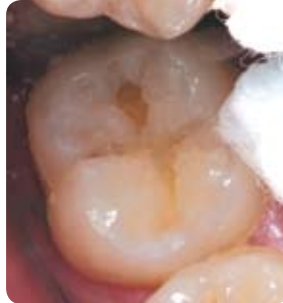Dr. J. Lucas



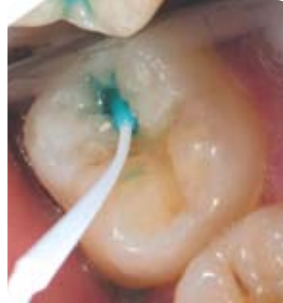Extra **TRANSLUCENCY**
Extra fast Extra fluoride

Fuji IX GP EXTRA is your first choice for restoring minimal carious lesions

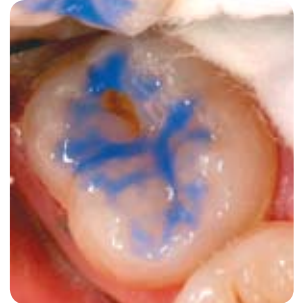The first cut of a tooth signals the start of a repeat restoration cycle that results in progressive loss of tooth structure as each restoration degrades and is subsequently replaced. Using glass ionomer cement as the durable interface with dentine is part of a long term strategy to minimise the biological cost to the tooth of replacement dentistry. Ideally replacement dentistry should be limited to resurfacing a degraded restoration while maintaining the internal seal with no further loss of tooth structure. Repairing and maintaining existing restorations is a core part of a minimal intervention philosophy.



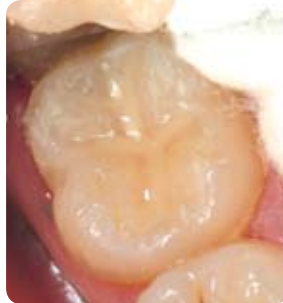Cavity preparation



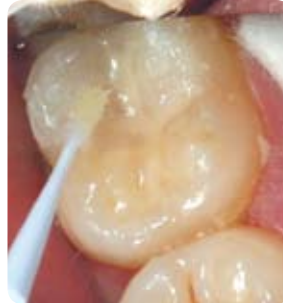Conditioner is applied to dentine



Un-cut enamel is acid etched



Fuji IX GP EXTRA is placed



G-COAT PLUS is applied to the glass ionomer and surrounding etched enamel

Dr. G. Millich

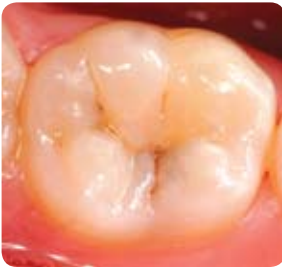


Larger occlusal restorations

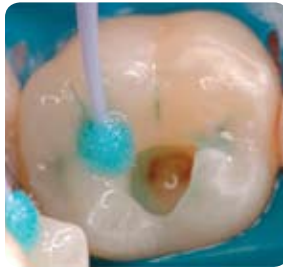In clinical situations where there is a higher occlusal load the use of a Fuji IX GP EXTRA and GRADIA DIRECT composite in a laminate technique is recommended. The cut-back sandwich technique

involves over filling the cavity with glass ionomer cement then cutting back to form the optimum shape/size cavity outline for the composite laminate. The snap set of Fuji IX GP EXTRA along with G-BOND's ability

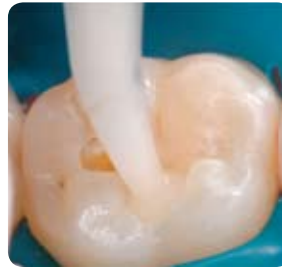to provide strong chemical adhesion between glass ionomer and composite has renewed popularity of this very successful technique.



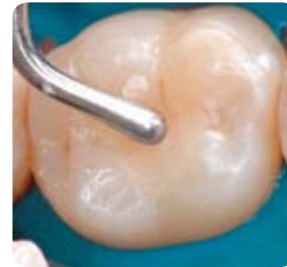Young adult presents with active caries and an initial lesion on 46



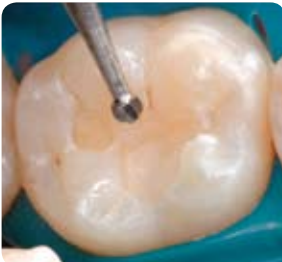Following cavity preparation CAVITY CONDITIONER is applied to remove the smear layer



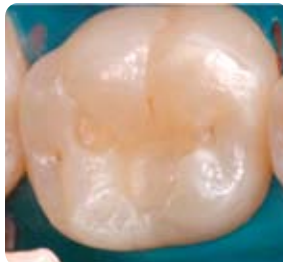Fuji IX GP EXTRA shade A2 is syringed into the cavity



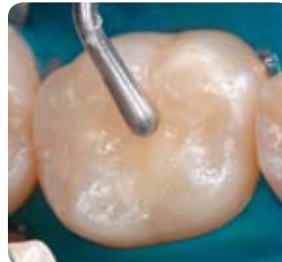Excess cement is removed. Note the excellent shade match of Fuji IX GP EXTRA



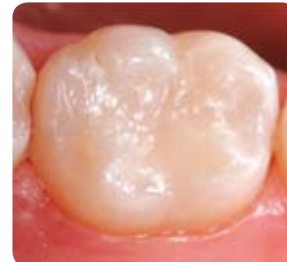2½ minutes from start of mix the cement is cut back to allow for a 2mm veneer of composite



A thin layer of G-BOND is applied to all surfaces, air dried with maximum air pressure and light cured



GRADIA DIRECT Posterior shade A2 is placed as an enamel replacement

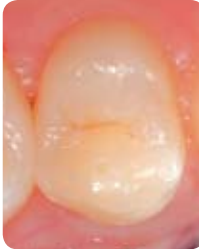

Completed restoration

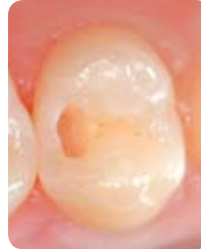Dr. S. Vouliotis

Tunnel Restorations

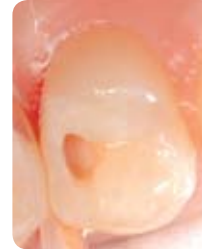Preserving the structural integrity of the peripheral rim is beneficial for the strength of posterior tooth. Proximal lesions can be accessed without compromising the rim by using a tunnel preparation technique to remove proximal decay.



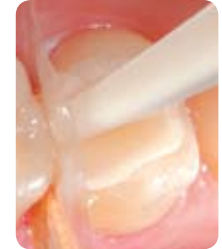Patient presents with a distal lesion on an upper first premolar



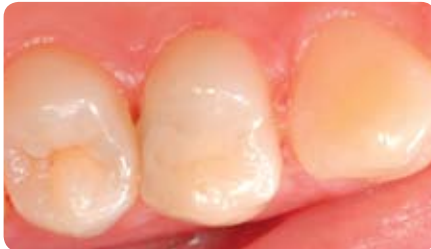A "T" access cavity is created in the enamel and caries removed with #5 round bur



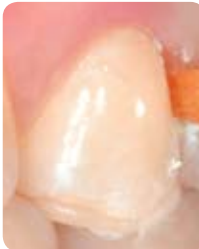A short Mylar strip is placed interproximally and wedged against the cavity preparation



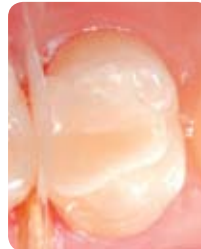A glass ionomer cement is placed to slightly overfill the cavity



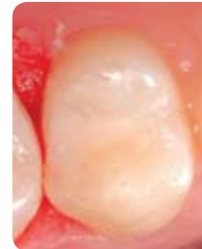Tunnel restoration 14 months after placement



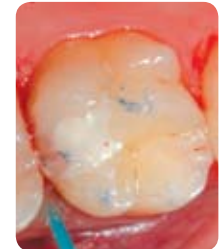
As the patient occludes the Mylar strip is pushed over the cement



The restoration is contoured and finished



Completed restoration: the most conservative and aesthetic option for restoring an initial Class II cavity



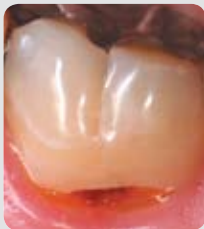A layer of protective varnish may reduce proximal surface degradation of the glass ionomer cement

Images first published in the ADA News Bulletin, No 358, 2007 and are reproduced with the permission of the Australian Dental Association Inc.

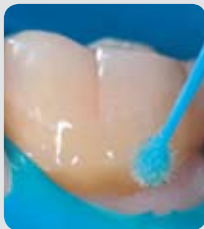Dr G. Knight

Cervical restorations

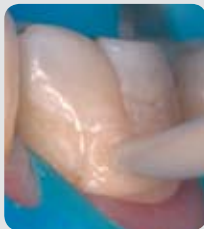The superior shade matching of Fuji IX GP EXTRA means more aesthetic results can be achieved with conventional glass ionomer cements in cervical cavities.



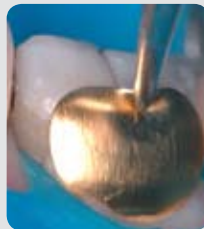
Cervical lesion



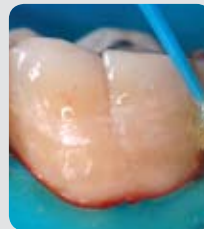Apply conditioner



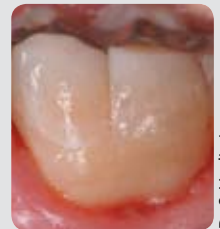
Inject Fuji IX GP EXTRA



Place cervical matrix



Apply G-COAT PLUS

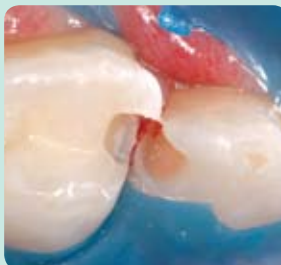


Finished restoration

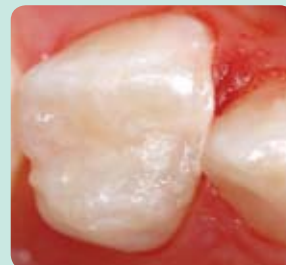Dr S. Vouliotis

Paediatric proximal restorations

Fuji IX GP EXTRA can be used as a restorative material in its own right or used in conjunction with composite in a laminate technique.



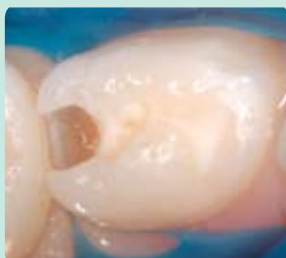Before



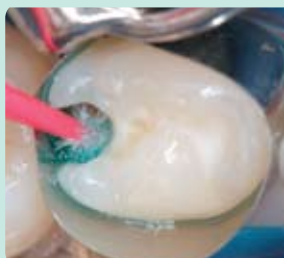Tooth 64 mesial restored with Fuji IX GP EXTRA shade B1

Dr J. Lucas

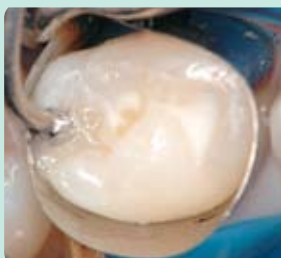Laminate technique



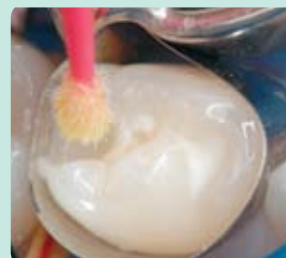Cavity preparation on Distal 84



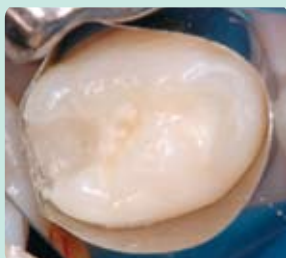
Apply conditioner for 10 seconds, wash and gently dry



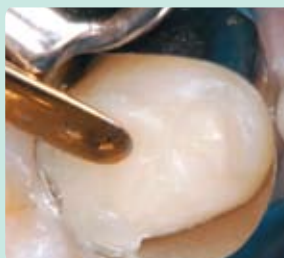Place Fuji IX GP EXTRA shade B1 to form a base



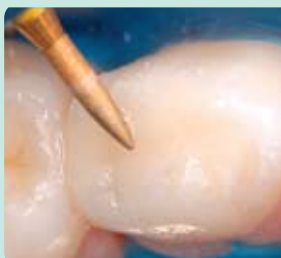Apply G-BOND for 10 seconds to the cut enamel and GIC base



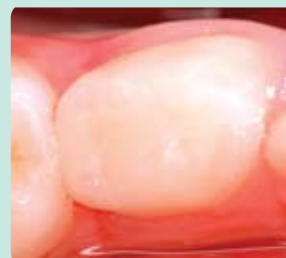G-BOND is vigorously air dried and light cured for 10 seconds



Shade A1 GRADIA DIRECT posterior composite is applied and light cured



Finish with fine diamonds



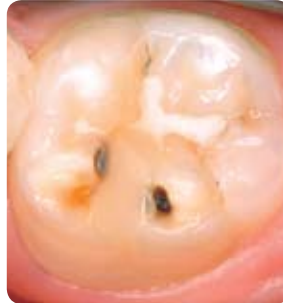Completed restoration

Dr J. Lucas

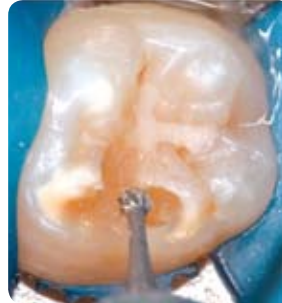Continuing caries

Despite existing fissure sealants new lesions will develop if a patient's caries risk remains high. For small lesions in permanent posterior teeth restoring with Fuji IX GP EXTRA and G-COAT PLUS provides a very useful combination of strength, aesthetics and protection.

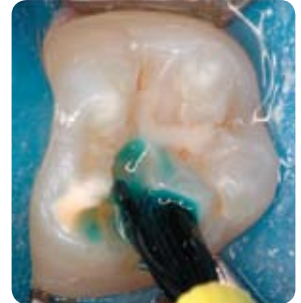G-COAT PLUS can be extended beyond the Fuji IX GP EXTRA restoration to include the existing resin fissure sealant as a strategy to help maintain the marginal integrity of the sealant.



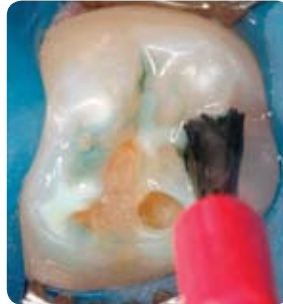New lesion on tooth 47



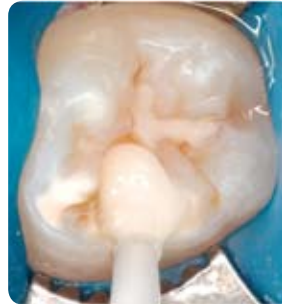Caries removal



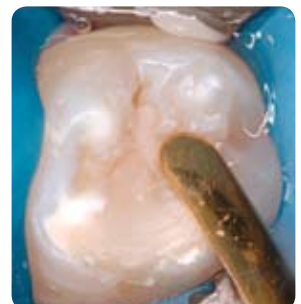
Apply conditioner



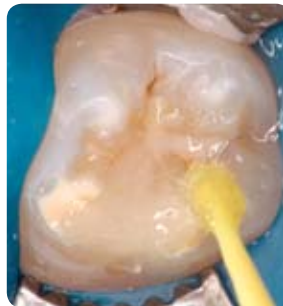Surrounding enamel and existing sealant are etched




Fuji IX GP EXTRA shade B1 is placed



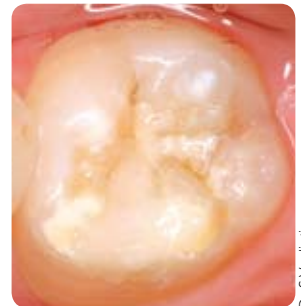Contour occlusal anatomy



G-COAT PLUS is applied to all enamel, sealant and GIC surfaces



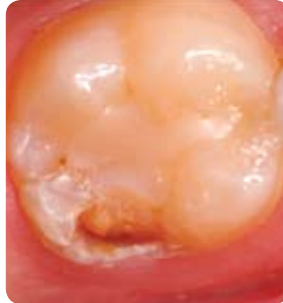Light cure for 20 seconds



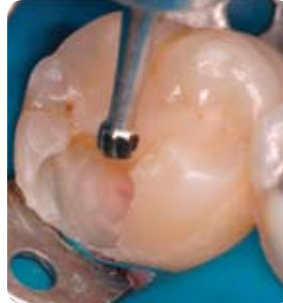Completed restoration

Continuing caries

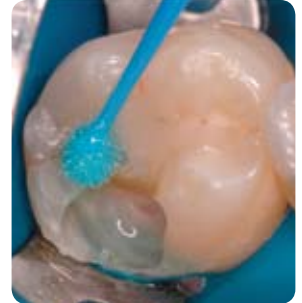New lesions can develop around existing restorations especially if hostile environmental factors remain unchanged. Fuji IX GP EXTRA is ideal as a transitional restorative for patients with active decay and as part of a pulp protection strategy.



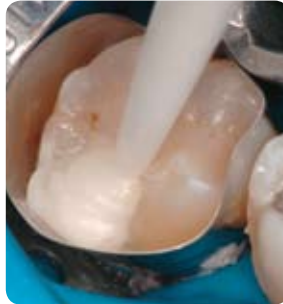New lesion on tooth 46



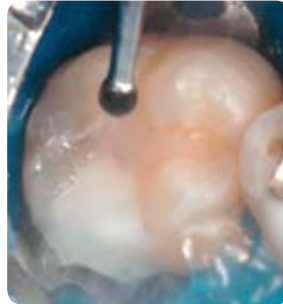Caries removal



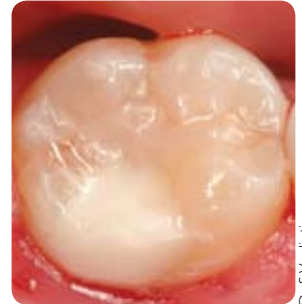Apply conditioner



Fuji IX GP EXTRA shade B1 is placed



Final finishing



Completed restoration

Dr. S. Vouliotis

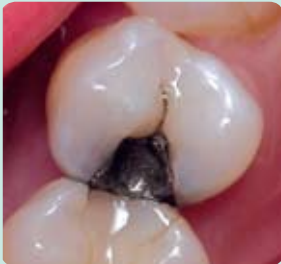

Extra **TRANSLUCENCY**
Extra fast Extra fluoride

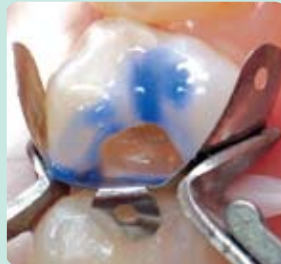Fuji IX GP EXTRA is ESSENTIAL for replacement dentistry

Replacing existing restorations

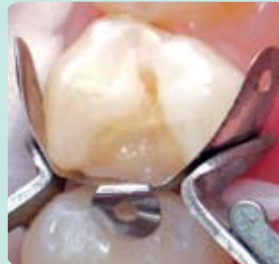When existing proximal restorations fail due to continuing caries activity it is a challenge to select the best tooth coloured restoration that will offer a durable seal, protection for the tooth, withstand an acidic oral environment yet be cost effective and aesthetic. In these situations a closed sandwich technique is suggested where Fuji IX GP EXTRA is able to seal and protect the tooth and then all exposed external surfaces are laminated with composite resin.



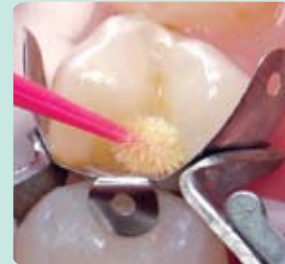An amalgam restoration in tooth 24 has recurrent caries and requires replacement



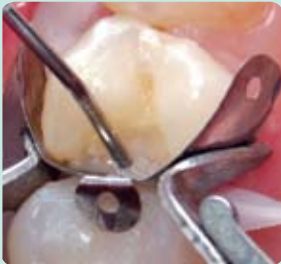Dentine is conditioned with 10% polyacrylic acid and enamel etched with 37% phosphoric acid gel



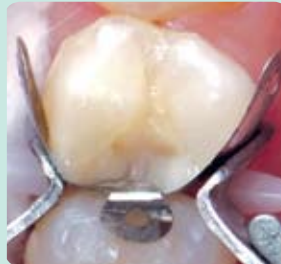Fuji IX GP EXTRA is injected into the cavity to form a base



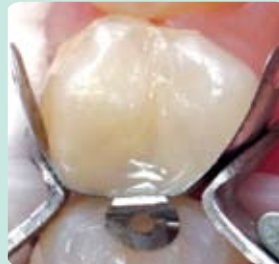G-BOND is applied to the etched enamel and Fuji IX GP EXTRA base. Light cure for 10 seconds



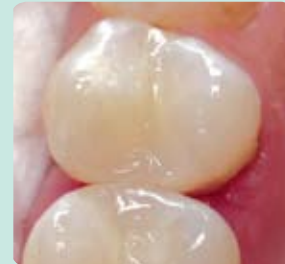A flowable resin is placed on the gingival margin and polymerized



GRADIA DIRECT Posterior (A2) is placed and sectioned into increments to reduce shrinkage stress



A final layer of GRADIA DIRECT Posterior Natural Translucent is placed and light cured

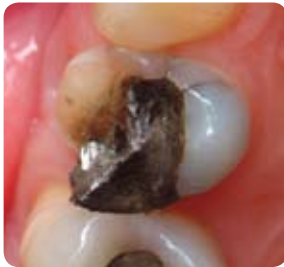

Completed restoration after finishing and polishing

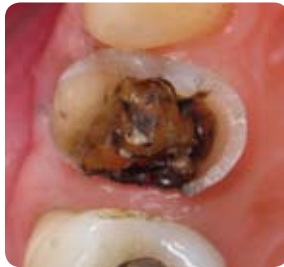Dr G. Millicich

Transitional restorations and cores

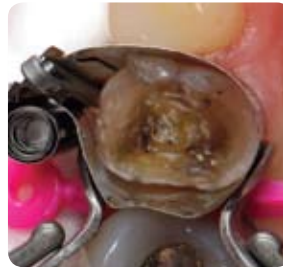Fuji IX GP EXTRA is an ideal transitional restorative material for emergency patients requiring immediate treatment for fractured cusps. Following placement of the transitional restoration the patient can re-appoint for a permanent restoration. Providing a good dentine ferrule can be cut the Fuji IX GP EXTRA transitional restoration can be used to form part of the core for a crown.



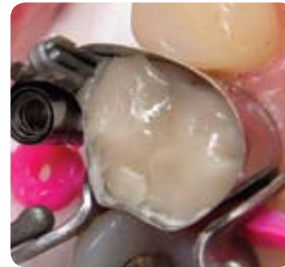Initial patient presentation



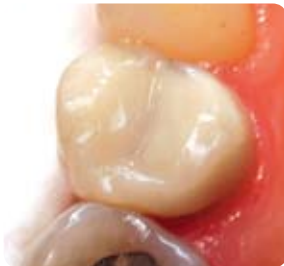Amalgam and fractured palatal cusp removed



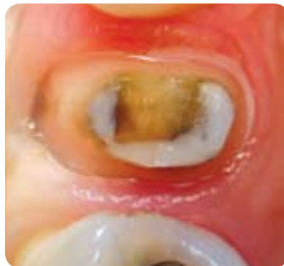Matrix in place



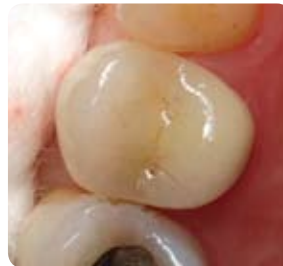Placement of Fuji IX GP EXTRA



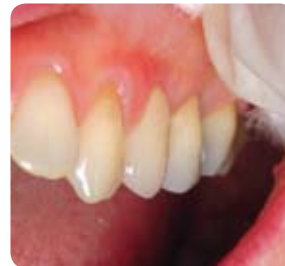Completed Fuji IX GP EXTRA transitional restoration



Subsequent crown preparation four weeks later



Fitted crown occlusal view



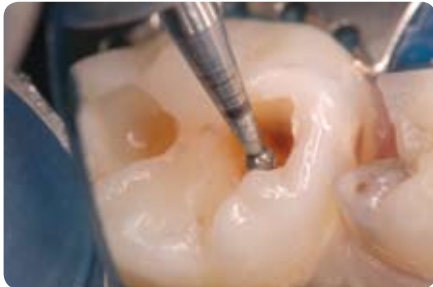
Fitted crown facial view

Dr. G. Miltich


Extra **TRANSLUCENCY**
Extra fast Extra fluoride

Achieving OPTIMUM clinical results with Fuji IX GP EXTRA

1. Cavity preparation

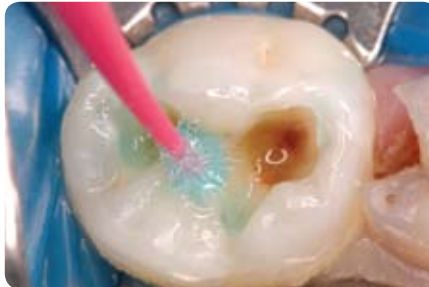


Ensure a clean, caries-free periphery around the DEJ. Fuji IX GP will help remineralise underlying dentine – therefore for teeth with deep lesions and a symptomless pulp it is suggested to leave softened dentine on the cavity floor rather than risk pulpal exposure. Fuji IX GP EXTRA uses a strontium containing glass which is reported to be more effective at remineralising soft dentine.



Remineralisation Hypermineralisation Remineralisation

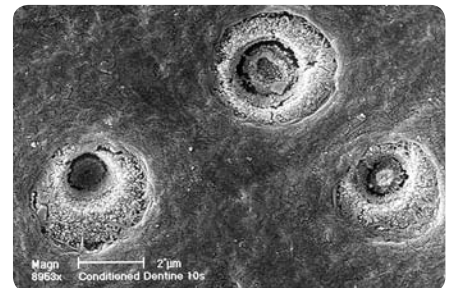
2. Apply conditioner for 10 seconds



CAVITY CONDITIONER is recommended to remove surface debris left following cavity preparation. Conditioning will also improve the surface energy so that Fuji IX GP EXTRA can better flow and adapt to the cavity floor and walls. The polyacrylic acid in CAVITY CONDITIONER will also prepare dentine and enamel for chemical adhesion without opening the dentine tubules. After washing off the conditioner gently dry to remove excess moisture without desiccating the tooth.



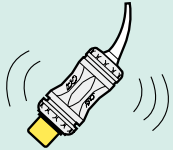
Dentine surface with smear layer intact



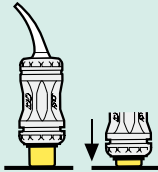
Dentine surface after treatment with polyacrylic acid conditioner

3. Capsule activation and mixing

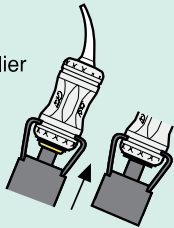
A Shake or tap to loosen powder.



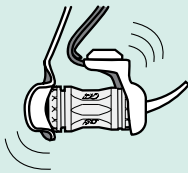
B Depress plunger.



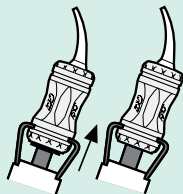
C Click once in capsule applicator to activate.



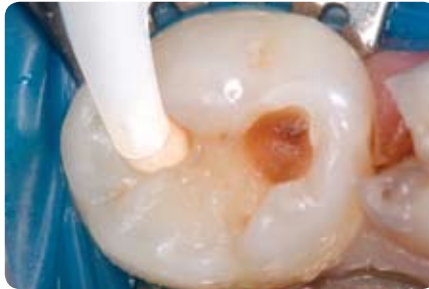D Mix for 10 seconds.



E Two clicks to prime capsule then syringe slowly.




4. Place Fuji IX GP EXTRA



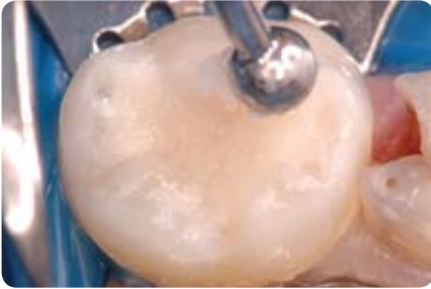Injection of Fuji IX GP EXTRA should be undertaken immediately following mixing while the cement has a free-flowing consistency. This will ensure intimate surface contact of the cement to the cavity walls and floor for optimum chemical adhesion, while minimising the risk of air entrapment and voids.

The formation of a strong chemically fused seal is the most significant benefit gained by using glass ionomer cement as the adhesive interface with tooth.

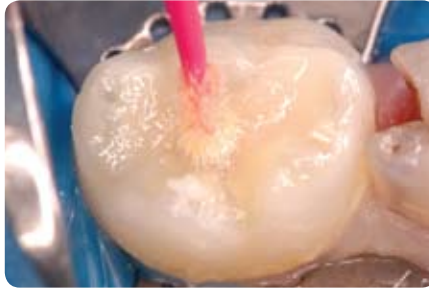


This SEM image identifies the acid resistant chemically fused seal (A) which appears as a raised ridge between the Fuji IX GP and dentine. The specimen section was taken from a tooth which had been restored with Fuji IX GP and subsequently extracted for unrelated reasons nine months later. The specimen was polished, etched for ten seconds to remove the smear layer and then a resin impression was taken to enable SEM evaluation.

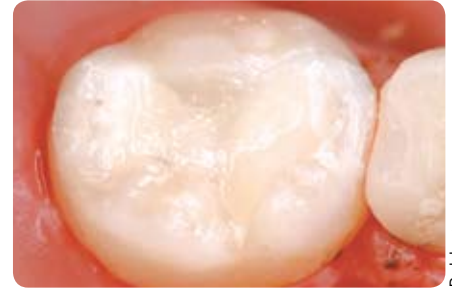
5. Contour the surface



6. Apply G-COAT PLUS




7. Finished restoration

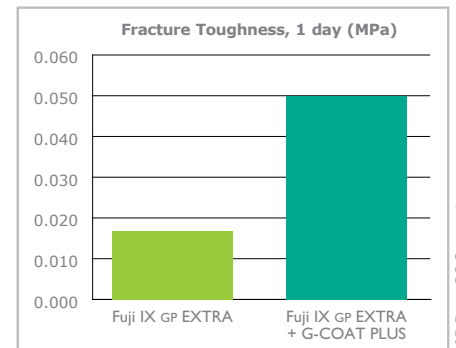


Dr. J. Lucas

For a high gloss finish, best possible strength and early wear resistance, apply a single layer of G-COAT PLUS and light cure. This will maintain the moisture balance within the glass ionomer while increasing the cement's fracture toughness through lamination strengthening. Over time this coating will gradually wear to expose a matured Fuji IX GP EXTRA which can then benefit from additional surface hardening as a result of calcium and phosphate uptake from saliva.



A – G-COAT PLUS B – 40 micron film thickness
C – Infiltration of G-COAT PLUS



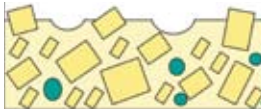R&D Dept. GC Corporation.

Strengthening your Fuji IX GP restorations

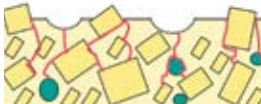– EXTRA, FAST and Regular

Lamination strengthening

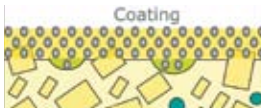G-COAT PLUS is a tough, nano-filled, self adhesive coating that will chemically bond to Fuji IX GP and surrounding tooth surfaces. These characteristics mean it has a lamination hardening effect when applied to Fuji IX GP that markedly increases the fracture toughness, early wear resistance and acid resistance of the cement.



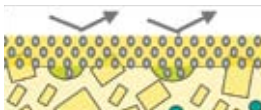
1. Glass ionomer cement



2. Mechanical stress concentrates on surface voids leading to crack propagation



3. G-COAT PLUS bonds to the surface and fills voids



4. Mechanical stress is dispersed by the toughened laminate layer



Achieving optimum maturation

Fuji IX GP gains strength over time due to maturation of the internal chemical reactions and surface strengthening due to the uptake of calcium and phosphate from saliva. GC Corporation R&D report the greatest improvement in strength is achieved by coating Fuji IX GP with a protective layer to allow internal cement maturation, and then over time allow delayed exposure to saliva to start the surface hardening process through uptake of calcium and phosphate. G-COAT PLUS is identified as the coating material of choice for this purpose.

Sandwich technique

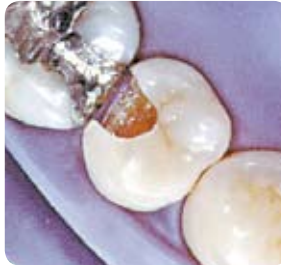An external restorative material can be placed over a base of Fuji IX GP in clinical situations where cavities are larger and under greater stress, or when restorations are placed in patients with highly acidic mouths. Composite resin is often the external material selected to laminate Fuji IX GP although amalgam and porcelain are options as well. The combination of composite and glass ionomer has proven to be very successful and can be further enhanced with the use of G-BOND as the adhesive link between the two. This is due to G-BOND's ability to both micromechanically and chemically bond the composite laminate to both the Fuji IX GP base and surrounding tooth surfaces.

Fuji IX

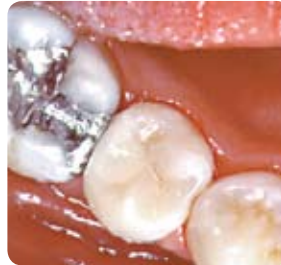The world's **FIRST** high strength glass ionomer for posterior use

In 1995 this patient required replacement of a class II composite restoration. After checking the occlusion and load bearing factors the operator decided to place a new high-strength glass ionomer material; Fuji IX. The reason – this new glass ionomer could provide the longevity of seal, ongoing protection and acceptable aesthetic results.

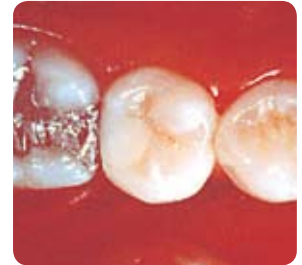In 2007 the results speak for themselves ...



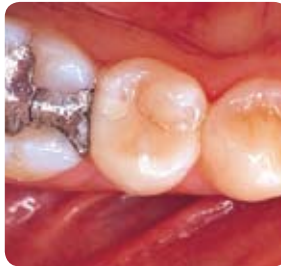Prepared cavity after conditioning
– 1995



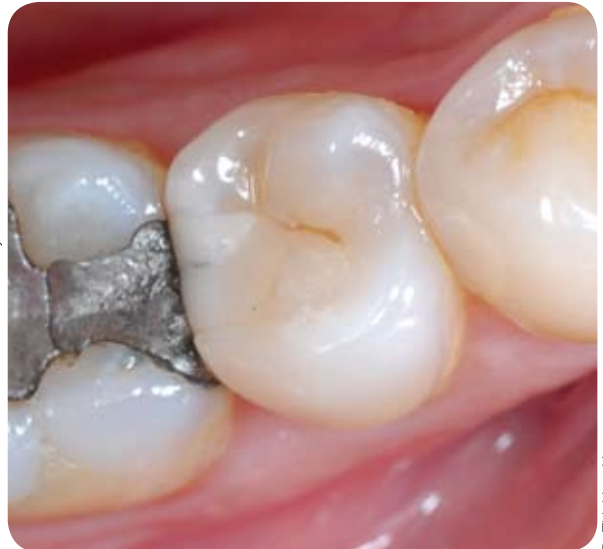Final result after finishing and
polishing – 1995




The same restoration three years
later – 1998



The same restoration six years later
– 2001



The same restoration twelve years later – 2007



Fuji IX GP EXTRA Physical properties

		Fuji IX GP EXTRA (GC)	Fuji IX GP (GC)	Fuji IX GP FAST (GC)	Ketac Molar Quick Aplicap (3M.ESPE)	Riva Self Cure FAST (SDI)
Lot Number	Condition	0512201	0306052	0306161	Los/Lot 002/010	0308051
Mixing Time [Sec.]		10"	10"	10"	10"	10"
Working Time** [Min., Sec.]	23°C	1'15"	2'00"	1'15"	1'00"	1'30"
Final Finishing Commencing Time** [Min., Sec.]	37°C, After starting mix	2'30"	6'00"	3'00"	–	3'00"
Surface Hardness** [Hv]	After 1 day	72(5)	74(3)	74(3)	49	42(2)
Compressive Strength* [MPa]	After 1 day After 1 week	255(14) 265(15)	220(9) 230(14)	268(10) 274(11)	221(25) 188(29)	153(7) 164(19)
Modulus of Elasticity** [GPa]	After 1 day	7.8(0.1)	8.3(0.5)	8.6(0.3)	6.2(0.2)	4.1(0.5)
Diametral Tensile Strength (MPa)	After 1 day	23(1)	22(2)	23(2)	16(3)	13(3)
Flexural Strength** [MPa]	After 1 day	25(1)	26(4)	26(3)	–	21(8)
Radiopacity** [mm Al]		2.3(0.2)	3.7(0.3)	3.7(0.3)	2.3(0.3)	2.1(0.3)
Bonding Strength** [MPa] with Cavity Conditioner	To Bovine Enamel, After 1 day	6.4(2.2)	5.9(1.7)	6.9(1.6)	4.4(1.0)	3.5(0.2)
	To Bovine Dentine, After 1 day	6.0(1.4)	4.4(1.6)	5.8(2.2)	3.6(0.7)	3.1(0.4)

* ISO 9917-1:2003 ** in-house test (): Standard Deviation

GC Corporation R&D Dept.



GC GOLD LABEL 9

1-1 pack
15g Powder, 8g Liquid
Shades: A2, A3, A3.5, B2
(also available in individual 15g Powder and 8g Liquid pack)

FUJI IX GP

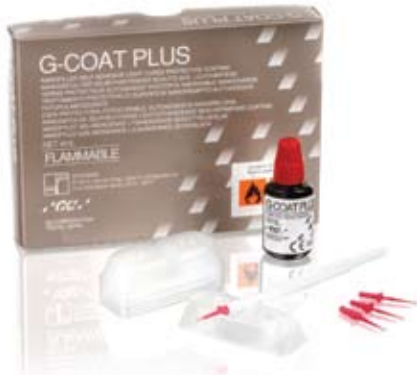Box 50 capsules
Shades: A2, A3, A3.5

FUJI IX GP FAST

Box 50 capsules
Shades: A2, A3, A3.5

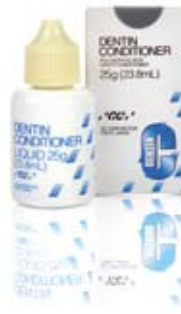FUJI IX GP EXTRA

Box 50 capsules
Shades: A2, A3, A3.5



G-COAT PLUS

Contains:
1 x 4ml bottle of G-Coat PLUS
50 x micro-tips
1 x micro-tip applicator
20 x disposable dispensing dishes



DENTIN CONDITIONER

25g (23.8ml) bottle
6g (5.7ml) bottle



GC Asia Dental Pte Ltd
Changi Logistics Centre
19 Loyang Way #06-27 Singapore 508724
Tel 65 + 6546 7588 Fax 65 + 6546 7577
www.gcasia.info Copyright © 2008